

# Quantitation of Zygomatic Complex Symmetry Using 3-Dimensional Computed Tomography

*Xi Gong, DDS,\* Ying He, DDS,† Yang He, DDS, MD,‡ Jin-gang An, DDS, MD,§ Yao Yang, DDS,|| and Yi Zhang, PhD, MD, DDS¶*

**Purpose:** To improve the clinical evaluation of the symmetry of the zygomatic complex (ZMC), the authors developed a new method to measure the eminence and width of the ZMC using 3-dimensional (3D) computed tomography (CT). The accuracy and reproducibility of the ZMC symmetry evaluation using this method were investigated.

**Materials and Methods:** Spiral CT was carried out in 50 volunteers with visually symmetric faces. Based on an exact craniofacial midsagittal plane, a 3D coordinate system was constructed and used to measure the eminence and width of the ZMC. Absolute differences between the bilateral eminences and widths were calculated as  $\Delta E$  and  $\Delta W$ , respectively. The ZMC eminence also was measured based on traditional methods using anatomic landmarks, and the bilateral absolute difference was calculated to serve as a control ( $\Delta cE$ ).

**Results:** The  $\Delta E$  value was lower than the  $\Delta cE$  value (0.6 vs 1.75 mm;  $P < .001$ ). None of the results for  $\Delta E$  were larger than 2 mm, and 7 results (3.5%) for  $\Delta W$  were larger than 2 mm. By comparison, 57 results (28.5%) for  $\Delta cE$  were larger than 2 cm ( $P < .001$ ). The intraclass correlation coefficient (ICC) indicated almost perfect agreement for inter- and intraexaminer reliabilities for  $\Delta E$  (ICC, 0.82 to 0.86) and  $\Delta W$  (ICC, 0.81 to 0.85) measurements, and moderate agreement for inter- and intraexaminer reliabilities was obtained for  $\Delta cE$  (ICC, 0.61 to 0.68) measurements.

**Conclusion:** This new method is practical and valuable in the clinical evaluation of ZMC symmetry.

© 2014 American Association of Oral and Maxillofacial Surgeons

*J Oral Maxillofac Surg* 72:2053.e1-2053.e8, 2014

The zygomatic complex (ZMC) contributes considerably to overall facial form,<sup>1</sup> and it is the second most frequently fractured facial bone.<sup>2</sup> Therefore, ZMC symmetry is of interest in the fields of trauma, reconstructive surgery, and esthetic plastic surgery, and its quantitative evaluation is essential for preoperative planning and postoperative assessment. However, owing to the irregular contours, lack of specific anatomic landmarks, and difficulty of midsagittal plane

determination, there is no generally accepted method for the measurement and evaluation of ZMC symmetry.<sup>3,4</sup>

Various methods have been reported for the assessment of ZMC symmetry. 1) Direct measurement of live subjects is time consuming and requires the use of sophisticated and possibly invasive techniques.<sup>3,5</sup> Moreover, this approach can be influenced by the subjective judgment of the examiners.<sup>4</sup> 2) Imaging

Received from the Department of Oral and Maxillofacial Surgery, Peking University School and Hospital of Stomatology, Beijing, China.

\*Resident.

†Resident.

‡Attending Physician.

§Assistant Professor.

||Resident.

¶Professor and Department Head.

This study was supported by the Capital Health Research and Development of Special and the National High-tech R&D Program of China (2009AA045201).

Address correspondence and reprint requests to Dr Zhang: Department of Oral and Maxillofacial Surgery, Peking University School and Hospital of Stomatology, 22 Zhong Guan Cun South Street, Beijing 100081, People's Republic of China; e-mail: [zhangyi2000@263.net](mailto:zhangyi2000@263.net)

Received June 5 2014

Accepted June 24 2014

© 2014 American Association of Oral and Maxillofacial Surgeons

0278-2391/14/01106-9

<http://dx.doi.org/10.1016/j.joms.2014.06.447>

measurement using anatomic landmarks of the ZMC has been used,<sup>6</sup> but none of the anatomic landmarks are located in the most prominent region of the ZMC, which, to a large extent, determines visual ZMC symmetry and thus midfacial symmetry.<sup>4,5</sup> 3) Imaging measurements, such as chromatographic analysis, of the volume of the ZMC have been reported,<sup>7</sup> but the available methods still have problems in the establishment of the midsagittal plane. Moreover, volume measurements provide the average difference in the location of the entire ZMC, rather than the most prominent portion of the ZMC. 4) Imaging measurements using the ZMC eminence have been described. The ZMC eminence is defined as the most prominent portion of the ZMC.<sup>4</sup> The measurement involves using radiography,<sup>8</sup> 2-dimensional (2D) computed tomography (CT),<sup>9</sup> and 3-dimensional (3D) CT.<sup>4,10</sup> Radiography is rarely used because its validity is limited by magnification and structural overlap. A practical method based on simple procedures for the measurement of bilateral ZMC eminences using 2D CT was described by Pham et al<sup>9</sup> in 2007. This method involves measurements based on the axial CT slice at the level of the zygomatic arch, just below the infraorbital rim (ZMC slice). This is recommended because the ZMC slice is useful for showing the status of the zygomatic arch and the projection of the malar eminences.<sup>11</sup> However, as a 2D measurement, the results of this method can be distorted by the patient's head position.<sup>4,12,13</sup> When the patient's head position is taken improperly, no single axial CT slice covers the most eminent points of the bilateral ZMC.<sup>12</sup> In other words, the right and left sides can be compared for symmetry only if scans are taken with the head properly positioned so that similar cuts are made bilaterally. In addition, the determination of the center point in this method is based on anatomic landmarks, calling its precision into question.<sup>8,14</sup> The 3D CT technique allows optional rotation of a virtual skull, which avoids the distortion caused by head position and provides an independent observation of organs and structures.<sup>13</sup> Thus, the 3D CT technique allows accurate quantitation of ZMC symmetry. However, the reported methods involve intricate procedures and lack evidence of their clinical practicability for the evaluation of ZMC symmetry. Therefore, in the present report, the authors propose a new 3D CT measurement method of the ZMC eminences based on a modification of the method of Pham et al, and they investigated its accuracy and reproducibility in the evaluation of ZMC symmetry in 50 volunteers.

## Materials and Methods

The study was conducted at the Peking University School and Hospital of Stomatology (Beijing, China).

Fifty healthy volunteers (25 men, 25 women; median age, 25 yr; age range, 18 to 35 yr) from northern China were included using the following criteria: 1) a visually symmetric face meeting the esthetic standards of a clinician and a layperson and 2) the absence of congenital craniofacial anomalies, injuries, or surgeries. This study was approved by the ethics committee for human experiments at the Peking University School and Hospital of Stomatology (PKUSSIRB-2011008) and was conducted in accordance with the Declaration of Helsinki guidelines for human research. All volunteers gave written informed consent to participate.

### MEASUREMENTS OF ZMC EMINENCE AND WIDTH

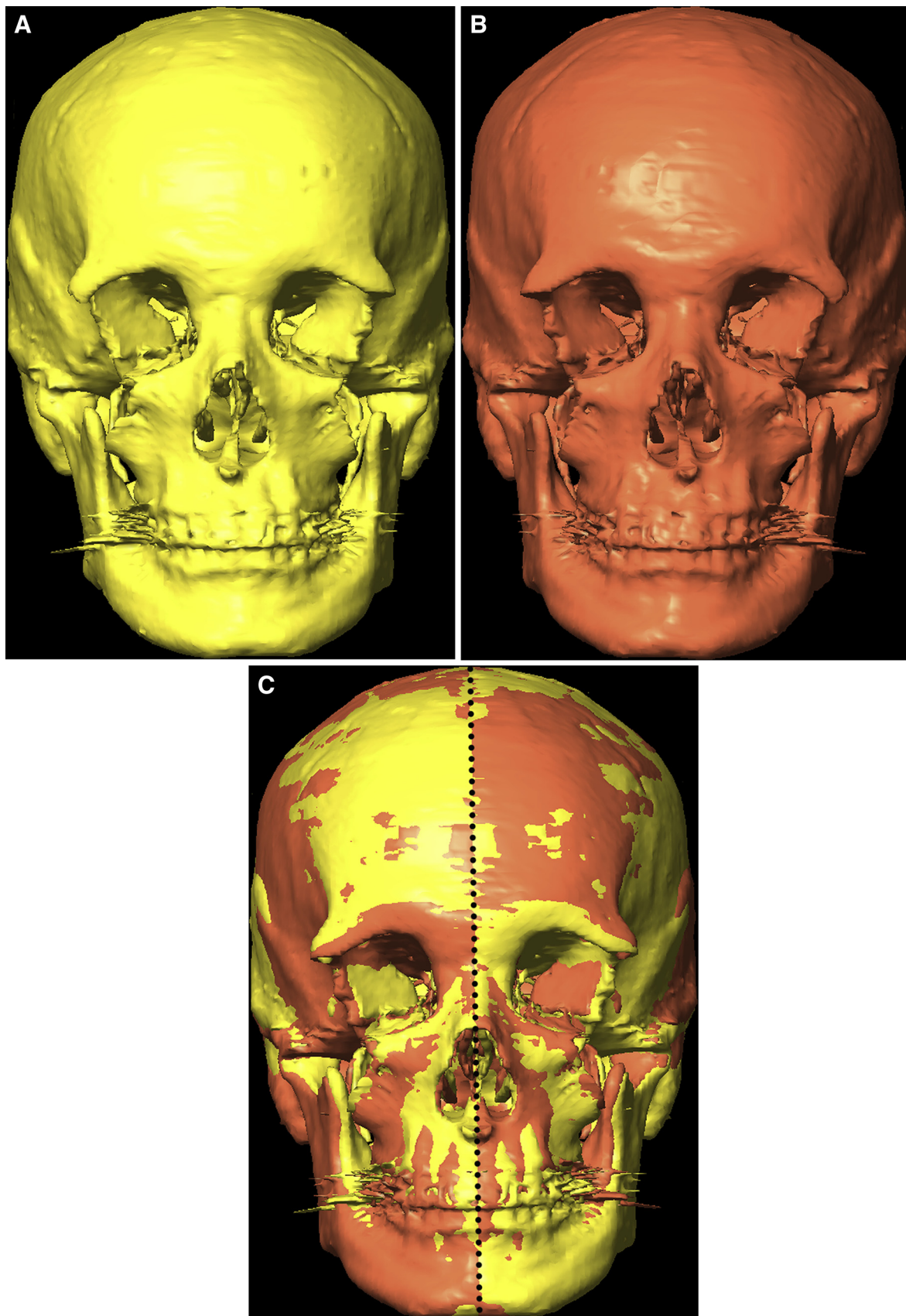
All spiral CT scans were acquired using the same machine (helical with 1.25-mm slice thickness; Bright Speed 16, GE Healthcare, Buckinghamshire, UK). Processed CT data were evaluated with iPlan CMF (BrainLAB, Feldkirchen, Germany) using Digital Imaging and Communications in Medicine files. Measurements of the ZMC eminence and width were carried out in 3 steps.

#### *Step 1: Construction of Midsagittal Plane*

A reconstructed 3D view of the skull was built with the auto-segmentation function in iPlan CMF. To prevent information bias, the 3D skull (Fig 1A) was reconstructed without bilateral ZMCs using Boolean subtraction. A preliminary cephalofacial midsagittal plane was built passing through the nasion and sella points and perpendicular to the Frankfurt horizontal (FH) plane, which is a horizontal plane represented in profile by a line between the orbitales (the lowest points on the margin of the orbit) and the auriculares (the highest points on the margin of the auditory meatus). Based on this plane, a mirrored skull (Fig 1B) was generated from the 3D skull. Then, the contour of the 3D skull was superimposed onto the mirrored skull to account for the fact that human skulls are not completely symmetric. After the best fit was achieved, the plane of symmetry was extracted and used as the final cephalofacial midsagittal plane (Fig 1C).

#### *Step 2: Construction of 3D Coordinate System*

A 3D coordinate system was created using 3 planes of reference. 1) The final midsagittal plane was used to compensate for the lateral obliqueness of a participant's head position. 2) Then, the FH plane was included and the skull was rotated slightly along the final midsagittal plane (like nodding up and down) to adjust the FH plane to be parallel to the horizontal plane (using the middle points when the bilateral orbitales and auriculares were not in a plane). This



**FIGURE 1.** Determination of the final cephalofacial midsagittal plane. The B, mirrored skull was superimposed on the A, original skull. C, After fitting, the combined skulls were regarded as an entirely new symmetric object, meaning that the new symmetric object is symmetric within itself and has an internal plane of symmetry so that the left and right halves are mirror images. This plane of symmetry was extracted and used as the final cephalofacial midsagittal plane (dotted line).

procedure was used to compensate for the sagittal obliqueness of a participant's head position and create a single axial image slice covering most of the bilateral ZMC (ZMC slice). 3) To construct a 3D coordinate system and to determine an origin point on the ZMC slice, the coronal plane was built vertically to the final cephalofacial midsagittal plane and passed through though the bilateral auriculares (using the middle points when the bilateral auriculares were not in a plane; Fig 2).

### Step 3: 3D-Based Measurements

After selecting the ZMC slice in the 3D coordinate system, the most prominent point of the zygomatic contour was identified and verified in the sagittal and coronal views. The ZMC eminence was defined as the linear distance between the most prominent point and the origin of the coordinate axis (Fig 3). The absolute difference between the bilateral eminences of the ZMC was calculated and recorded as  $\Delta E$ . Similarly, the linear distance between the most lateral point on the zygomatic arch and the final midsagittal plane was defined as the ZMC width (Fig 4).  $\Delta W$  was calculated as the absolute difference between the bilateral ZMC widths.

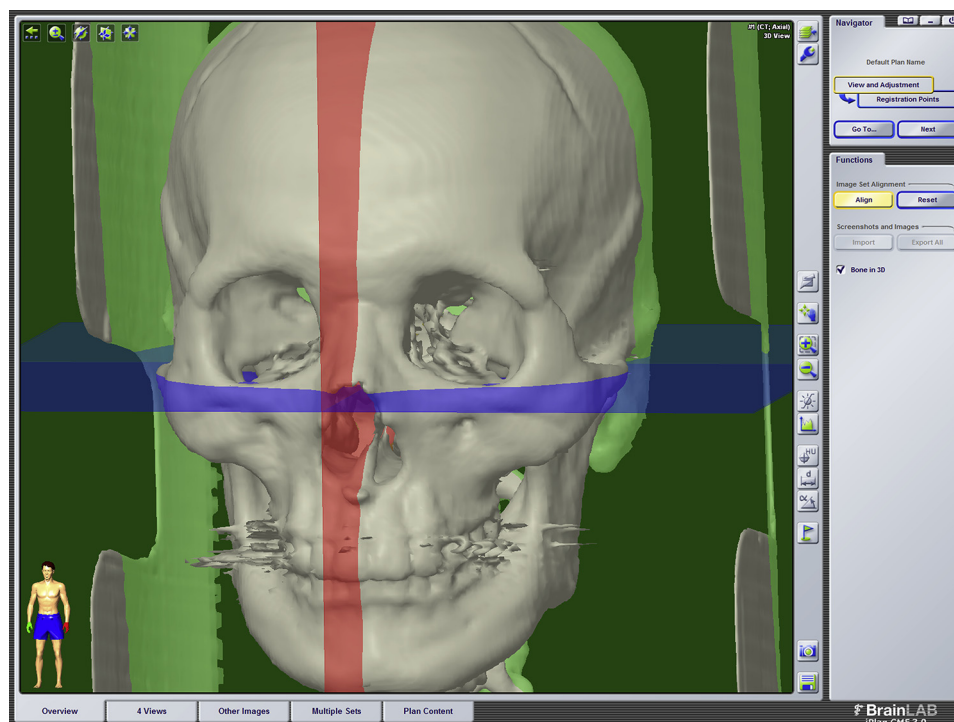
A 3D coordinate system based on the preliminary midsagittal plane, the FH plane, and the coronal plane was generated as a control. The axial image slice

covering most of the bilateral ZMC in this control 3D coordinate system (control slice) was selected. The linear distance between the most prominent point of the zygomatic contour and the center point based on the clivus at the skull base<sup>9</sup> was measured (Fig 5).  $\Delta cE$  was calculated in the same manner as the control.

### REPRODUCIBILITY AND ACCURACY OF ZMC SYMMETRY EVALUATION

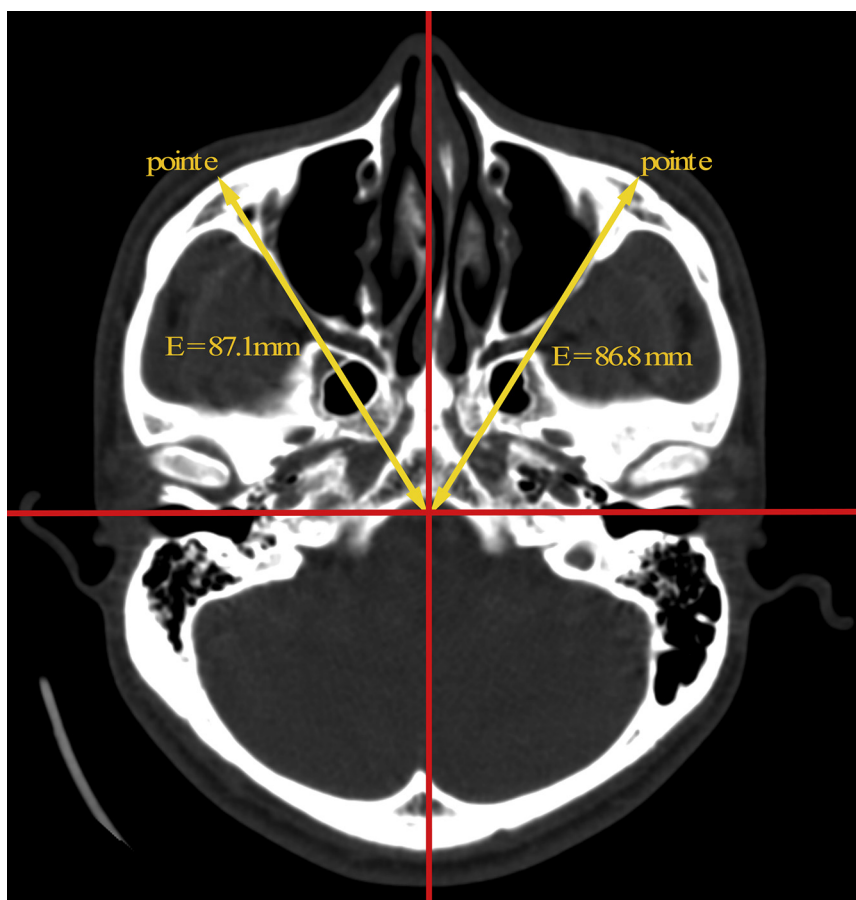
All measurements were repeated twice by each of 2 examiners in all 50 participants within a 1-week interval. All measurements were performed on the left and then on the right side of the ZMC. The 2 examiners were residents in oral and maxillofacial surgery with more than 1 year of experience in operating the iPlan CMF software. To minimize bias, the participant's information on the display screen of the computer was hidden from the examiners and the measurements were recorded by another assessor.

Skull measurements with differences larger than 2 mm between the right and left sides are considered clinically acceptable.<sup>15,16</sup> Therefore, for the participants in the present study with visually symmetric faces,  $\Delta E$ ,  $\Delta W$ , and  $\Delta cE$  values larger than 2 mm were regarded as inconsistent with clinical perception.



**FIGURE 2.** Construction of the 3-dimensional coordinate system. A 3-dimensional coordinate system was created using 3 planes of reference: the final midsagittal plane (red), the Frankfort horizontal plane (blue), and the coronal plane passing through the bilateral auriculares (green).

Gong et al. *Quantitation of Zygomatic Complex Symmetry*. *J Oral Maxillofac Surg* 2014.



**FIGURE 3.** Measurement of the zygomatic complex eminence. The most prominent points (e) of the zygomatic contours were identified on the zygomatic complex slice (axial slice covering most of the bilateral zygomatic complex) determined by the final cephalofacial midsagittal plane. Then, the point was then adjusted in the sagittal and coronal views. The zygomatic complex eminence (E) was calculated as the linear distance between point e and the origin of the 3-dimensional coordinate system.

Gong et al. *Quantitation of Zygomatic Complex Symmetry*. *J Oral Maxillofac Surg* 2014.

#### STATISTICAL ANALYSIS

The median and interquartile range were computed for numerical data, and the proportion was calculated for categorical data. Values of  $\Delta E$  and  $\Delta cE$  were compared using the Wilcoxon signed-rank test. Differences larger than 2 mm in the measurement rates between  $\Delta E$  and  $\Delta cE$  were evaluated with the  $\chi^2$  test. A  $P$  value less than .05 (2-tailed) was considered statistically significant. Intra- and interexaminer reliabilities were assessed with the intraclass correlation coefficient (ICC) for the classes of measured values ( $\Delta E$ ,  $\Delta W$ ,  $\Delta cE$ ). ICC values range from 0 to 1; values of 0.61 to 0.8 are interpreted as substantial agreement, and values of 0.81 to 1.0 indicate almost perfect agreement.<sup>17</sup> Statistical analyses were carried out using SPSS 19.0 (SPSS, Inc, Chicago, IL).

#### Results

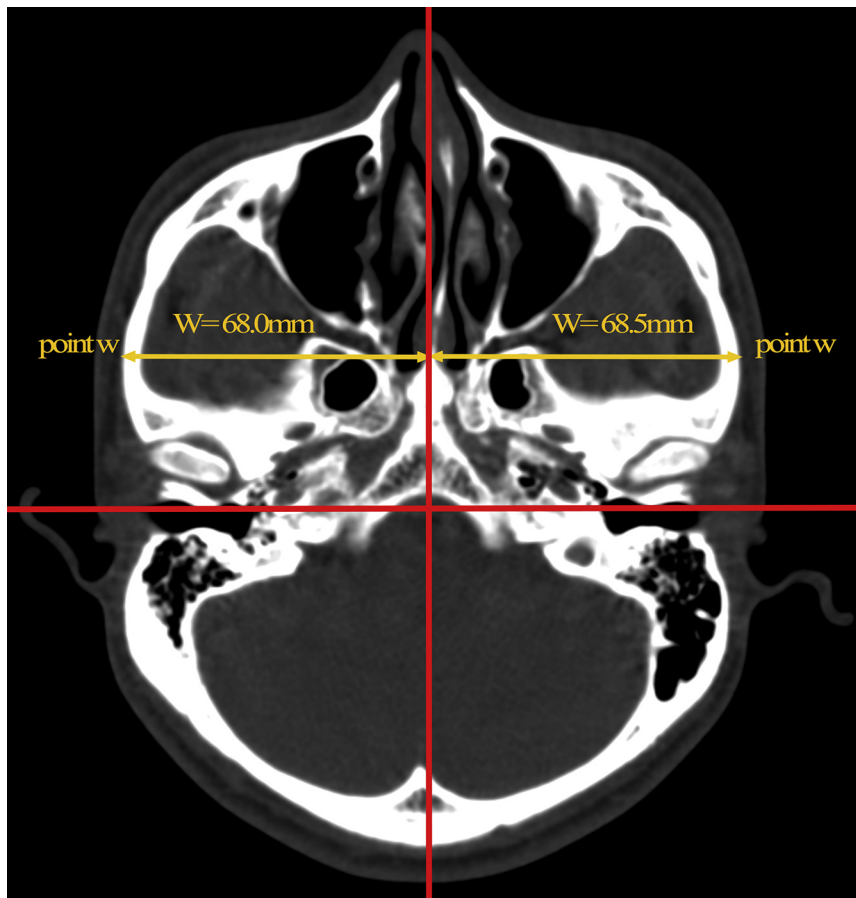
The  $\Delta E$  values were lower than the  $\Delta cE$  values (0.6 vs 1.75 mm;  $P < .001$ ). More importantly, no  $\Delta E$  values

exceeded 2 mm, whereas  $\Delta cE$  values exceeding 2 mm occurred in 53 cases (28.5%;  $P < .001$ ). The median value of  $\Delta W$  was 1.00 mm (interquartile range, 0.50 to 1.48), with 3.5% of results being larger than 2 mm (Table 1).

The ICCs for the intraexaminer reliability of  $\Delta E$  for the 2 examiners were 0.86 and 0.83, showing almost perfect agreement. Almost perfect agreement was shown by the interexaminer analysis for  $\Delta E$  (ICC, 0.86). The ICC of  $\Delta W$  also showed almost perfect agreement for intra- and interexaminer analyses (ICC, 0.81 to 0.84). For  $\Delta cE$  measurements, moderate agreement was obtained for the 2 examiners (ICCs, 0.63 and 0.68) and between examiners (ICC, 0.61; Table 2).

#### Discussion

The objective of this study was to develop a clinically applicable, reliable, and quantitative method for the evaluation of ZMC symmetry. In this study, the technique for exact determination of the



**FIGURE 4.** Measurement of the zygomatic complex width. The most lateral points ( $w$ ) of the zygomatic arches were identified on the zygomatic complex slice (axial slice covering most of the bilateral zygomatic complex) and adjusted in the coronal view. The width of the zygomatic complex ( $W$ ) was calculated as the linear distance between point  $w$  and the final midsagittal plane.

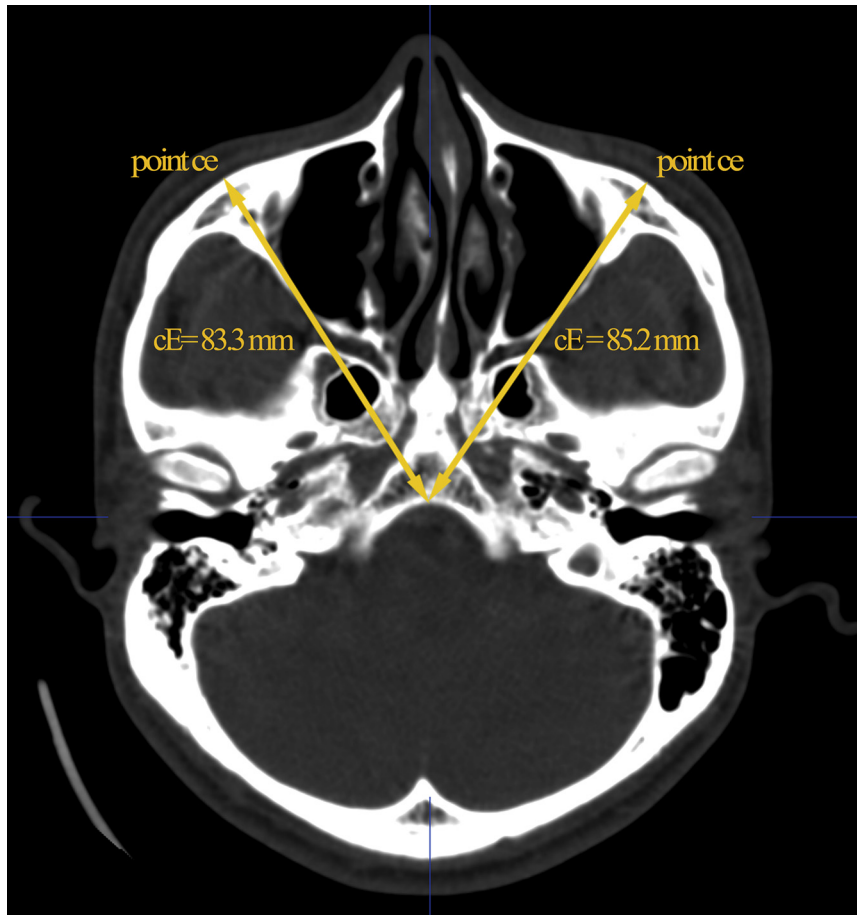
Gong et al. *Quantitation of Zygomatic Complex Symmetry. J Oral Maxillofac Surg* 2014.

cephalometric midsagittal plane was introduced to the ZMC symmetry evaluation. Based on this midsagittal plane and the 3D CT technique, the present study developed a standard cephalofacial 3D coordinate system, in which a simple method for the measurement of the ZMC eminence and width was defined. Then, the measurements were performed repeatedly in 50 volunteers to test the value of this system for ZMC symmetry evaluation. The results showed very good reproducibility and accuracy.

Accurate identification of the midsagittal plane is critical in evaluating symmetry.<sup>6,15,16</sup> The methods reported for the evaluation of ZMC symmetry most commonly used a midsagittal plane (or a center point) generated from anatomic landmarks.<sup>3-5,8</sup> In the present study, the authors developed an improved technique to determine the cephalometric midsagittal plane. This technique, which was first described by Greiner et al,<sup>18</sup> takes advantage of all data points in intact regions of the skull instead of using single anatomic landmarks. This technique was first used in the evaluation of the eyeball position,<sup>18</sup>

and then in a facial asymmetry evaluation in adult patients with cleft lip and palate.<sup>1</sup> It has been shown to produce accurate and reliable midsagittal planes that can be used in comparative studies.<sup>14,18,19</sup> In contrast, 6 frequently used cephalometric midsagittal planes described in the literature were investigated by Damstra et al<sup>14</sup> They concluded that care must be taken when using these planes for diagnosis and treatment planning for craniofacial asymmetry. This technique was modified in the present study because the 3D skull was reconstructed without the bilateral ZMC using Boolean subtraction, to prevent matching of the 3D skull and the mirrored skull through the bilateral ZMC. This procedure is important because construction of the midsagittal plane based on the use of the bilateral ZMC to match the skulls will invalidate the subsequent measurement of the difference in bilateral ZMC eminences.

The FH plane also was used in the present study. Adjustment of the FH plane to be parallel to the horizontal plane is important, because it could compensate for the sagittal obliqueness of a patient's head



**FIGURE 5.** Measurement of the zygomatic complex eminence without the final cephalofacial midsagittal plane as a control. The most prominent points (ce) of the zygomatic contours were identified on the control zygomatic complex slice (axial slice covering most of the bilateral zygomatic complex) in relation to the preliminary cephalofacial midsagittal plane. The control eminence of the zygomatic complex (cE) was calculated as the linear distance between point ce and the cephalofacial center point determined by an anatomic landmark (the clivus at the base of the skull).

Gong et al. *Quantitation of Zygomatic Complex Symmetry.* *J Oral Maxillofac Surg* 2014.

position. Correct adjustment of the FH plane creates the correct ZMC slice, which provides the critical circumstances for measurement of the ZMC eminence and width.

Identifying the exact locations of the measuring points is essential for an accurate, reproducible, and

quantitative measurement of ZMC symmetry. The ZMC eminence (the most prominent portion of the ZMC<sup>4</sup>) determines the visual zygoma symmetry to a large extent.<sup>4,11</sup> However, its location appears different when observed from alternative viewpoints, making its exact position difficult to

**Table 1. ABSOLUTE DEVIATION OF BILATERAL ZYGOMATIC COMPLEX EMINENCES AND WIDTHS**

	Examiner 1 (First)	Examiner 1 (Second)	Examiner 2 (First)	Examiner 2 (Second)	Sum
ΔE (mm)	0.70 (0.40-1.10)	0.70 (0.30-1.10)	0.85 (0.40-1.30)	0.85 (0.38-1.20)	0.80 (0.40-1.20)*
ΔW (mm)	1.00 (0.30-1.50)	1.00 (0.50-1.40)	1.00 (0.50-1.53)	0.90 (0.50-1.43)	1.00 (0.50-1.48)
ΔcE (mm)	1.50 (1.08-2.00)	1.50 (1.08-1.90)	1.60 (0.88-2.23)	1.35 (0.68-2.43)	1.50 (0.83-2.10)*

Note: Values are presented as median (interquartile range).

Abbreviations: ΔcE, control absolute deviation of bilateral eminences; ΔE, absolute deviation of bilateral eminences; ΔW, absolute deviation of bilateral widths.

\* *P* < .05 by Wilcoxon signed-rank test.

Gong et al. *Quantitation of Zygomatic Complex Symmetry.* *J Oral Maxillofac Surg* 2014.

**Table 2. INTRACLASS CORRELATION COEFFICIENTS WITH 95% CONFIDENCE INTERVALS FOR INTRA- AND INTEREXAMINER AGREEMENT FOR THE ZYGOMATIC COMPLEX EMINENCE AND WIDTH**

	Examiner 1		Examiner 2		Interexaminer	
	ICC	95% CI	ICC	95% CI	ICC	95% CI
$\Delta E$	0.86	0.75-0.92	0.83	0.71-0.91	0.82	0.67-0.90
$\Delta W$	0.81	0.67-0.89	0.85	0.74-0.92	0.83	0.69-0.90
$\Delta cE$	0.63	0.35-0.79	0.68	0.44-0.82	0.61	0.32-0.78

Abbreviations: CI, confidence interval; ICC, intraclass correlation coefficient;  $\Delta cE$ , control absolute deviation of bilateral eminences;  $\Delta E$ , absolute deviation of bilateral eminences;  $\Delta W$ , absolute deviation of bilateral widths.

Gong et al. *Quantitation of Zygomatic Complex Symmetry. J Oral Maxillofac Surg* 2014.

identify.<sup>5</sup> The cephalofacial center point is traditionally determined by the anatomic landmarks of the skull base.<sup>9</sup> However, this determination is questionable because there are no anatomic landmarks located exactly at the center point. In the present study, the authors improved on these methods by creating a 3D coordinate system in which the origin is defined as the cephalofacial center point, and the viewpoint of different examiners is standardized to improve the accuracy and reproducibility of locating the ZMC eminence. In addition, adjustments of the sagittal and coronal views make this new method even more accurate.

Based on the exact midsagittal plane, the 3D coordinate system, and the exact location of the measuring points, the present method shows good clinical practicability. The differences between bilateral ZMC eminences for all study participants with visually symmetric faces were smaller than 2 mm, which is consistent with visual facial esthetic appreciation. In contrast, only 71.5% of results obtained using the control measurement method, which was based on the determination of a midsagittal plane and a center point as commonly described in the literature,<sup>14</sup> met this criterion. The new method also is more reproducible than the control method. In addition to the eminences, ZMC width is of concern to some patients who complain of an excessively wide or narrow face. For this reason, width measurement with good accuracy and precision is included in this method for ZMC symmetry evaluation.

This method can be used to assess the degree of ZMC asymmetry in patients with unilateral facial deformity and provide surgical targets for preoperative computer-aided design in trauma or esthetic plastic surgery. This method also is valuable for comparing

the treatment effects of different surgical techniques involved in ZMC asymmetry.

The authors have proposed a new method for the quantitative measurement of the eminence and width of the bilateral ZMC and showed that this new method provides good reproducibility and consistency compared with the clinical perception of the ZMC symmetry evaluation.

## References

- Meyer-Marcotty P, Alpers GW, Gerdes AB, et al: Impact of facial asymmetry in visual perception: A 3-dimensional data analysis. *Am J Orthod Dentofacial Orthop* 137:168, 2010
- Covington DS, Wainwright DJ, Teichgraber JF, et al: Changing patterns in the epidemiology and treatment of zygoma fractures: 10-Year review. *J Trauma* 37:243, 1994
- Czerwinski M, Martin M, Lee C: Quantitative topographical evaluation of the orbitozygomatic complex. *Plast Reconstr Surg* 115:1858, 2005
- Moubayed SP, Duong F, Ahmarani C, et al: A novel technique for malar eminence evaluation using 3-dimensional computed tomography. *Arch Facial Plast Surg* 14:403, 2012
- Nechala P, Mahoney J, Farkas LG: Maxillozygion anthropometric landmark: A new morphometric orientation point in the upper face. *Ann Plast Surg* 41:402, 1998
- Furst IM, Austin P, Pharoah M, et al: The use of computed tomography to define zygomatic complex position. *J Oral Maxillofac Surg* 59:647, 2001
- He Y, Zhang Y, An JG, et al: Zygomatic surface marker-assisted surgical navigation: A new computer-assisted navigation method for accurate treatment of delayed zygomatic fractures. *J Oral Maxillofac Surg* 71:2101, 2013
- de Moraes ME, Hollender LG, Chen CS, et al: Evaluating craniofacial asymmetry with digital cephalometric images and cone-beam computed tomography. *Am J Orthod Dentofacial Orthop* 139:e523, 2011
- Pham AM, Rafii AA, Metzger MC, et al: Computer modeling and intraoperative navigation in maxillofacial surgery. *Otolaryngol Head Neck Surg* 137:624, 2007
- Holmes S, Goldner S, Bridle C, et al: Evaluation of complex craniomaxillofacial fractures by a new three-dimensional planning system. *Br J Oral Maxillofac Surg* 44:416, 2006
- Saini P: *Oral and Maxillofacial Trauma* (ed 4). St Louis, MO, Saunders, 2013. p 358
- Park SH, Yu HS, Kim KD, et al: A proposal for a new analysis of craniofacial morphology by 3-dimensional computed tomography. *Am J Orthod Dentofacial Orthop* 129:600, 2006
- Muramatsu A, Nawa H, Kimura M, et al: Reproducibility of maxillofacial anatomic landmarks on 3-dimensional computed tomographic images determined with the 95% confidence ellipse method. *Angle Orthod* 78:396, 2008
- Damstra J, Fourie Z, De Wit M, et al: A three-dimensional comparison of a morphometric and conventional cephalometric midsagittal planes for craniofacial asymmetry. *Clin Oral Investig* 16:285, 2012
- Farkas LG, Cheung G: Facial asymmetry in healthy North American Caucasians: An anthropometrical study. *Angle Orthod* 51:70, 1981
- Ellis E III, Kittidumkerng W: Analysis of treatment for isolated zygomaticomaxillary complex fractures. *J Oral Maxillofac Surg* 54:386, 1996
- Landis JR, Koch GG: The measurement of observer agreement for categorical data. *Biometrics* 33:159, 1977
- Greiner G, Niemann H, Ertl T, et al: *Vision, Modeling, and Visualization*. Amsterdam, IOS, 2002. p 332
- Hartmann J, Meyer-Marcotty P, Benz M, et al: Reliability of a method for computing facial symmetry plane and degree of asymmetry based on 3D-data. *J Orofac Orthop* 68:477, 2007