

Micro-computed Tomographic Comparison of Nickel-Titanium Rotary *versus* Traditional Instruments in C-Shaped Root Canal System

Xingzhe Yin, MDS,* Gary Shun-pan Cheung, MDS, MSc, PhD,[†] Chengfei Zhang, DDS, PhD,*[‡] Yoshiko Murakami Masuda, DDS, PhD,[‡] Yuichi Kimura, DDS, PhD,[§] and Koukichi Matsumoto, DDS, PhD[‡]

Abstract

Introduction: The purpose of this study was to assess the efficacy of instrumentation of C-shaped canals with ProTaper rotary system and traditional instruments by using micro-computed tomography (micro-CT). **Methods:** Twenty-four mandibular molars with C-shaped canals were selected in pairs and sorted equally into 2 groups, which were assigned for instrumentation by ProTaper rotary system (ProTaper group) or by K-files and Gates-Glidden burs (Hand Instrument group). Three-dimensional images were constructed by micro-CT. The volume of dentin removed, uninstrumented canal area, time taken for instrumentation, and iatrogenic error of instrumentation were investigated. **Results:** Hand Instrument group showed greater amount of volumetric dentin removal and left less uninstrumented canal area than ProTaper group ($P < .01$). The time needed for instrumentation was shorter for ProTaper group than for Hand Instrument group ($P < .05$). No instrument breakage occurred in both groups, but more conspicuous procedural errors were detected in Hand Instrument group than for ProTaper group. **Conclusions:** It was concluded that ProTaper rotary system maintained the canal curvature with speediness and few procedural errors, whereas traditional instrumentation can clean more canal surface. (*J Endod* 2010;36:708–712)

Key Words

C-shaped canals, micro-computed tomography, NiTi rotary files, root canal instrumentation

From the *Department of Special Dentistry, Peking University School and Hospital of Stomatology, Beijing, China; [†]Comprehensive Dental Care, Endodontics, Faculty of Dentistry, University of Hong Kong, HKSAR, China; [‡]Department of Endodontics, Showa University Dental Hospital, Tokyo, Japan; and [§]Division of Endodontics, Department of Conservative Dentistry, Ohu University School of Dentistry, Fukushima, Japan.

Address requests for reprints to Dr Chengfei Zhang, Area of Endodontics, Comprehensive Dental Care, Faculty of Dentistry, University of Hong Kong, HKSAR, China. E-mail address: zchengfei@yahoo.com.

0099-2399/\$0 - see front matter

Copyright © 2010 American Association of Endodontists. doi:10.1016/j.joen.2010.01.003

The C-shaped canal system is characterized by a C-shaped groove that connects one or more canals in cross section. There are many variations in the anatomical configurations along the length of the canal system in these types of teeth (1, 2). The C-shaped canal system might appear completely normal-looking at the level of the pulp chamber (3), but the apical anatomy can be extremely complex (4, 5). These complex root canal configurations can be a great challenge to recognize, shape and clean, and obturate under a clinical setting.

As an important step of endodontic treatment, root canal instrumentation is directly related to debridement and disinfection; it also has a direct impact on the subsequent obturation. During the last decade, nickel-titanium (NiTi) rotary instruments have become increasingly popular, with numerous studies indicating a superior ability of NiTi instruments to maintain the original canal curvature, to produce a well-tapered root canal form suitable for obturation, and to complete the instrumentation process expeditiously (6, 7). However, studies of shaping ability of both NiTi and traditional (stainless steel) instruments were mostly performed on regular or uncomplicated root canals but rarely on complex root canal systems such as the C-shaped canals.

In recent years micro-computed tomography (micro-CT) has proved to be a valuable tool for evaluating the morphologic changes in the canal shape before and after instrumentation (8, 9). Not only a cross-sectional examination of the root but also the 3-dimensional (3D) configuration of the canal might be evaluated at high resolution (9). Other advantages of micro-CT technique include little or no specimen preparation required and the nondestructive nature of the process.

The purpose of this study was to assess the morphologic changes of the C-shaped canal system before and after instrumentation by using a NiTi rotary system or traditional stainless steel instruments. The main parameters to be investigated included the volume of dentin removed, amount of uninstrumented area, time taken for instrumentation, and the presence of any iatrogenic errors.

Materials and Methods

Preparation of Specimens

Sixty-seven human mandibular molars with fused roots were selected from a pool of extracted teeth and stored in 10% neutral buffered formalin solution. The teeth had completed root formation and were without visible apical resorption. Specimens were scanned at an isotropic resolution of 22 μm by using a micro-focus x-ray CT system (SMX-90CT; Shimadzu, Kyoto, Japan), without probing or exploration of the canals that might alter the initial canal anatomy. An individual pedestal for each tooth was made with a self-curing resin (Unifast III; GC Corporation, Tokyo, Japan). Fifty-three teeth were identified as having a C-shaped canal system according to the method of Fan et al (2). A 3D image of each tooth was reconstructed from the micro-CT data in software (TRI/3D-Bon; Ratoc System Engineering, Kyoto, Japan). Then 24 of the 53 mandibular molars with a C-shaped canal were selected in pairs (Fig. 1); each pair in the 2 groups ($n = 12$) was matched with respect to the type of pulp floor (3), 3D configuration (10), and the number of canals and apical foramina. The crown of each tooth was sectioned approximately 2 mm above the cemento-enamel junction

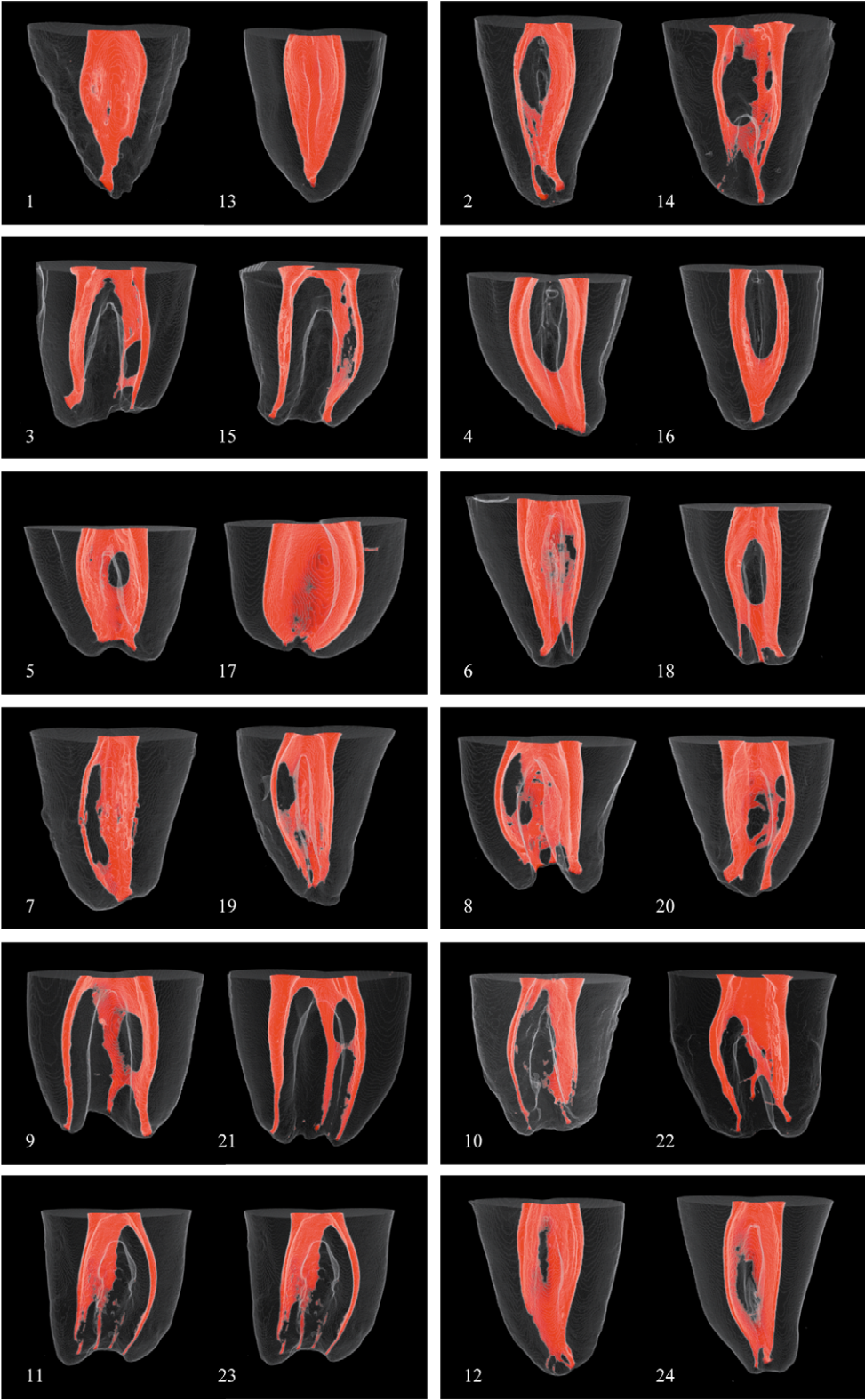


Figure 1. Reconstructed 3D images of all 12 pairs of C-shaped canals before instrumentation, selected according to the type of pulp floor, 3D configuration, and number of main canals and apical foramina.

and discarded. After endodontic access cavity preparation, a size 10 K-file was passively introduced into each canal until its tip was seen at the apical foramen. The working length was established by subtracting 1 mm from this measurement. Each group was instrumented either with a crown-down approach by using the ProTaper rotary instruments (Dentsply Maillefer, Ballaigues, Switzerland) or with the step-down technique by using K-files (Dentsply Maillefer) and Gates-Glidden burs (Dentsply Maillefer). All canal instrumentation was completed by one operator.

ProTaper Group

Crown-down Approach with ProTaper Rotary Instruments. A size 15 K-file was introduced into the canal by using a watch-winding motion, until it was felt to be loosely fitting. Then the ProTaper rotary system was used according to the manufacturer's instructions. Each instrument of the sequence was passively introduced into the canals at a rotation rate of 250 rpm. When it encountered any resistance or had reached the working length, they were pulled out slowly and gently, while being directed against the wall opposite the furcation area (11). Apical preparation was finished by the F3 instrument.

Hand Instrument Group

Step-down Technique with Hand Instruments. Teeth in Hand Instrument group were instrumented with the step-down technique, as described by Goerig et al (12). After a size 15 K-file could be introduced into the canal, a #2 Gates-Glidden bur was used to prepare the canal to the middle third, followed by a #3 to 2 mm shorter than the previous instrument and a #4 at the orifice level to form the straight-line access. Then size 15, 20, 25, and 30 K-files were used to the working length. Apical step-back filing was done by using size 35 and 40 files at 1-mm interval. The canal was finally recapitulated with a size 30 K-file.

For both groups, 3% H₂O₂ and 5.25% NaOCl were used as irrigants, and a size 10 K-file was used to verify patency. The instrumentation time was recorded from the introduction of the 15 K-file into the canal to the end of instrumentation.

Micro-CT Measurements

A micro-focus x-ray CT system was used with a voxel size of $44 \times 44 \times 44 \mu\text{m}^3$ at 90 kV to scan the specimens before and after instrumentation. The scanning procedure for 1 stack (276 slices) took 30 minutes. The 160–266 slices of interest volumes were selected from the orifice to the apex of the canals. A 3D image was constructed after filtering and thresholding in software (TRI/3D-Bon). The individual pedestal for each tooth and preregistered tooth position ensured repositioning and same orientation of the specimens in the micro-CT machine. The reconstructed 3D images before and after instrumentation were superimposed over each other, guided by the outer root contour. Measurements and evaluations were made by using similar criteria reported from previous studies (9, 13, 14).

Volumetric Analysis. The preoperative volume of the canal was determined by the voxel number of the canal, which was labeled in red, and the postinstrumented canal in green. After superimposition of the two 3D images, the color label of overlapping voxels was changed into yellow automatically by the software. The volume of dentin removed was counted from the number of green voxels after superimpositioning by the software (TRI/3D-Bon).

Area Analysis. The surface of the root canal wall was rendered on both the preinstrumentation and postinstrumentation images and then

superimposed. To evaluate the amount of uninstrumented surface area, it was assumed that those surface voxels remaining in the same position preoperatively and postoperatively represented the uninstrumented regions of the canal wall. Theoretically, the untouched area should be represented by voxels in yellow on the superimposed image. However, as a result of the complexity of the C-shaped canal system, a few red voxels were observed in all cases; these were also considered as part of the untouched area in our present study.

Iatrogenic Errors. The superimposed images were rotated through 360 degrees, and the number of teeth with iatrogenic errors caused by the instrumentation was recorded, including presence of zip, ledge, and perforation.

Statistical Analysis

The paired samples *t* test was used to determine the difference in the mean value between the 2 experimental groups for the volume of dentin removed, uninstrumented root canal area, and time taken for instrumentation. The amounts of iatrogenic errors were compared by using the χ^2 analysis. A *P* value of less than .05 was regarded as significant.

Results

Of the 24 selected C-shaped canals, the mean initial volume and surface area for the 2 groups were (ProTaper) $9.2 \pm 3.45 \text{ mm}^3$ and $89.58 \pm 20.84 \text{ mm}^2$ and (Hand Instrument) $9.66 \pm 3.24 \text{ mm}^3$ and $91.67 \pm 24.31 \text{ mm}^2$, respectively. There was no significant difference between the 2 groups before canal instrumentation. The preinstrumentation and postinstrumentation images were superimposed for differences in canal volume and surface area (Fig. 2).

Volume of Dentin Removed

A mean volume of 3.45 mm^3 of dentin was removed in ProTaper group, and mean of the percentage of removed dentin volume to volume after instrumentation was 27.7%. The corresponding values for Hand Instrument group were 7.67 mm^3 and 45.0%, respectively. The difference between the 2 groups was significant (Table 1).

Uninstrumented Canal Surface Area

The mean area of uninstrumented canal walls for ProTaper Group was 54.15 mm^2 , and mean of the percentage of untouched canal area to surface area before instrumentation was 59.6%. For Hand Instrument group, 41.6% of the walls, or 37.62 mm^2 of the canal walls, was not instrumented. The difference, again, was significant (Table 1).

Time Taken for Instrumentation

The time taken to complete the instrumentation for the teeth in ProTaper Group (6.75 ± 2.48 minutes) was significantly shorter than in Hand Instrument Group (8.93 ± 2.97 minutes) ($P < .05$). However, when the time required for preparing each canal was compared, the 2 instrumentation methods (ProTaper Group, 3.17 ± 1.05 minutes vs Hand Instrument group, 4 ± 1.47 minutes) were not significantly different ($P > .05$).

Iatrogenic Error of Root Canal Instrumentation

There was no instrument breakage for both groups. For the amount of iatrogenic errors observed, there was no significant difference between the 2 groups for the presence of ledge (2 in ProTaper group vs 1 in Hand Instrument group) and perforation (0 in ProTaper group vs 1 in Hand Instrument group), but Hand Instrument group

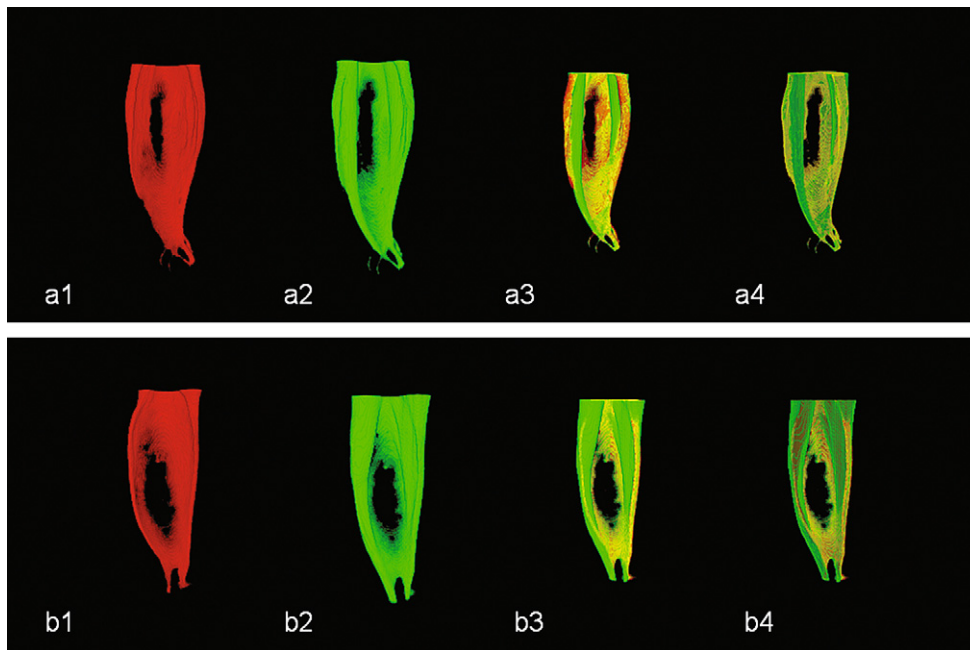


Figure 2. Reconstructed images of a pair of specimens (top row, ProTaper group; bottom row, Hand Instrument group): preinstrumentation (*a1, b1*) and post-instrumentation (*a2, b2*). Images were superimposed for determining the changes in canal volume (*a3, b3*) and the instrumented areas (*a4, b4*); the overlapped regions were turned into yellow automatically by the software.

presented more zip than ProTaper group (0 in ProTaper Group vs 5 in Hand Instrument group) ($P = .037$, Fisher exact test).

Discussion

The anatomical configuration of the C-shaped canal is rather complex. Many studies have shown that the C-shaped canal system can vary in the number and the shape of the main canal along the length of the root (1, 2, 10). Therefore, it is not always possible to predict the pulp canal configuration on the basis of the appearance of the canal orifices only (3, 5). The apical part of the C-shaped canal is also highly variable, with the presence of accessory canals, lateral canals, intercanal communications, and apical deltas in 11%–41% of cases (4). All these anatomical variations would make the debridement of the C-shaped canal system rather difficult to accomplish. There is also a scarcity of reports of the effect of various preparation techniques on such canal systems. Although numerous studies have shown the ability of NiTi rotary systems to maintain the original canal curvature and to produce a well-tapered root canal form in an acceptable time (6, 7), most of the instrumentation was performed on teeth with simple anatomy rather than complex systems including C-shaped canals.

Micro-CT technique has evolved into an exciting tool for experimental endodontics (8). The spatial resolution of the reconstructed

images has been improved over time from an original 127 μm (15) to 19.6 μm for recent machines (13, 14). However, the improvement in resolution is characterized by a longer scanning time for a closer z-resolution and a longer reconstruction period for a greater amount of data. In this study an isotropic resolution of 22 μm was used; the scanning of the entire tooth was achieved in one single sweep.

In view of the complex anatomy of C-shaped canal systems, 53 teeth with C-shaped canal system were first identified, and their cross sections (total 60–90 slices divided into apical, middle, and coronal thirds) were categorized by using a modification of Melton’s classification (1, 2). Then the teeth were selected in pairs that were matched with respect to the type of pulp floor (3), 3D configuration (10), and number of main canals and apical foramina. This gave a total of 12 pairs of teeth; the mean values of initial canal volume and root canal surface area were similar for both groups. However, even though the samples were matched for both groups, there could still be some variations in other details such as isthmus or interconnection between the main canals in different canal levels. For simplification, the quantitative analysis was not separated into apical, middle, and coronal thirds, but values were measured collectively over the entire canal lengths.

The results from the present study indicate that the traditional instrumentation method with the step-down technique removed more

TABLE 1. Volume of Removed Dentin and Uninstrumented Root Canal Surface Area by Superimposing Matched Images (means \pm standard deviations)

Group	Volume of removed dentin		Uninstrumented root canal surface area	
	Volume (mm^3)	Percent*	Area (mm^2)	Percent [†]
ProTaper group	3.45 \pm 1.35	27.7 \pm 12.1	54.15 \pm 18.94	59.6 \pm 12.1
Hand Instrument group	7.67 \pm 3.23	5.0 \pm 13.6	37.62 \pm 10.05	41.6 \pm 7.0
<i>P</i> value	<.001	.002	.039	<.001

P value: results of comparison between ProTaper group and Hand Instrument group (paired *t* test).

*Percentage of removed dentin volume to canal volume after instrumentation.

[†]Percentage of uninstrumented canal area to canal area before instrumentation.

dentin than NiTi rotary technique with ProTaper instruments. This might be related to the use of Gates-Glidden burs in the former group, which removed more dentin in the coronal and middle thirds of the root than NiTi rotary files (14). On the other hand, the traditional hand instrumentation technique resulted in significantly less uninstrumented surface area than rotary files, which might be related to the use of hand files in a circumferential filing motion and anticurvature filing direction (11).

Regardless of the instrumentation technique used, a large proportion of canal surface remained untouched after root canal preparation. The mean amount of uninstrumented canal surface was 50.6% for all specimens in our study. This value was higher than that of previous studies, probably because most other studies were performed on specimens with canals of round or oval cross section (7, 13, 16). Typically, the main canals of the C-shaped canal systems are connected by tiny ribbon-like isthmi in which NiTi instruments could hardly be inserted. Moreover, the high flexibility and the special design have allowed the NiTi rotary file to be self-centering in the lumen of the main canals but have made it rather impossible to be pressed against a specific region of the canal walls in an attempt to clean out the isthmus areas. C-shaped canals instrumented with NiTi engine-files always showed 2 or 3 circular bulges amidst the arc-shaped canal system.

Although the C-shaped canals instrumented by NiTi rotary instruments showed higher percentage of uninstrumented canal surface than manual K-files, the NiTi group produced less straightening, less apical canal transportation, and fewer incidences of perforations. Although NiTi rotary files should still be the instruments of choice for preparing C-shaped canals (17), from the results of this study it can be recommended that the 2 techniques be combined to obtain better debridement in clinical practice. After instrumentation by NiTi rotary instruments, K- or H-files could be passively introduced into the canal, and filing could be specifically directed toward the isthmus areas. However, according to the high percentage of untouched canal area of C-shaped canal systems in both groups, the use of chemical agents and other modalities (such as sonication and ultrasonication) for cleaning and disinfection cannot be overemphasized in the treatment of the C-shaped root canal system.

References

1. Melton DC, Krell KV, Fuller MW. Anatomical and histological features of C-shaped canals in mandibular second molars. *J Endod* 1991;17:384–8.
2. Fan B, Cheung GS, Fan M, Gutmann JL, Bian Z. C-shaped canal system in mandibular second molars: part I—anatomical features. *J Endod* 2004;30:899–903.
3. Min Y, Fan B, Cheung GS, Gutmann JL, Fan M. C-shaped canal system in mandibular second molars: part III—the morphology of the pulp chamber floor. *J Endod* 2006;32:1155–9.
4. Cheung GS, Yang J, Fan B. Morphometric study of the apical anatomy of C-shaped root canal systems in mandibular second molars. *Int Endod J* 2007;40:239–46.
5. Fan B, Min Y, Lu G, Yang J, Cheung GS, Gutmann JL. Negotiation of C-shaped canal systems in mandibular second molars. *J Endod* 2009;35:1003–8.
6. Bergmans L, Van Cleynenbreugel J, Wevers M, Lambrechts P. Mechanical root canal preparation with NiTi rotary instruments: rationale, performance and safety—status report for the American Journal of Dentistry. *Am J Dent* 2001;14:324–33.
7. Guelzow A, Stamm O, Martus P, Kielbassa AM. Comparative study of six rotary nickel-titanium systems and hand instrumentation for root canal preparation. *Int Endod J* 2005;38:743–52.
8. Rhodes JS, Pitt Ford TR, Lynch JA, Liepins PJ, Curtis RV. Micro-computed tomography: a new tool for experimental endodontology. *Int Endod J* 1999;32:165–70.
9. Peters OA, Laib A, Rueggeger P, Barbakow F. Three-dimensional analysis of root canal geometry by high-resolution computed tomography. *J Dent Res* 2000;79:1405–9.
10. Gao Y, Fan B, Cheung GS, Gutmann JL, Fan M. C-shaped canal system in mandibular second molars: part IV—3-D morphological analysis and transverse measurement. *J Endod* 2006;32:1062–5.
11. Abou Rass M, Frank AL, Glick DH. The anticurvature filing method to prepare the curved root canal. *J Am Dent Assoc* 1980;101:792–4.
12. Goerig AC, Michelich RJ, Schultz HH. Instrumentation of root canals in molar using the step-down technique. *J Endod* 1982;8:550–4.
13. Peters OA, Schonberger K, Laib A. Effects of four Ni-Ti preparation techniques on root canal geometry assessed by micro computed tomography. *Int Endod J* 2001;34:221–30.
14. Peru M, Peru C, Mannocci F, Sherriff M, Buchanan LS, Pitt Ford TR. Hand and nickel-titanium root canal instrumentation performed by dental students: a micro-computed tomographic study. *Eur J Dent Educ* 2006;10:52–9.
15. Nielsen RB, Alyassin AM, Peters DD, Carnes DL, Lancaster J. Microcomputed tomography: an advanced system for detailed endodontic research. *J Endod* 1995;21:561–8.
16. Rhodes JS, Pitt Ford TR, Lynch JA, Liepins PJ, Curtis RV. A comparison of two nickel-titanium instrumentation techniques in teeth using microcomputed tomography. *Int Endod J* 2000;33:279–85.
17. Cheung LH, Cheung GS. Evaluation of a rotary instrumentation method for C-shaped canals with micro-computered tomography. *J Endod* 2008;34:1233–8.